

# Memory: Clinical Disorders

Andrew E Budson, *Edith Nourse Rogers Memorial Veterans Hospital, Bedford, Massachusetts, USA*

Bruce H Price, *McLean Hospital, Belmont, Massachusetts, USA*

There are different forms of memory in the brain that use distinct anatomical structures to process various types of information in a variety of ways. Many disease processes can disrupt one or more of these forms of memory.

## Introduction

Although memory is usually robust and accurate, different disease processes can disrupt memory and cause either distortions or outright failure. The goal of this article is to provide an overview of the six basic forms of memory, their relevant neuroanatomy (Figure 1) and the clinical disorders that disrupt them (Table 1). By ‘a form of memory’, we mean a way in which the brain processes information that is available for use at a later time, with or without conscious awareness. If additional criteria are met related to the class of experiences remembered, the type of information processed, and dissociations between task, then the stronger notion of a ‘memory system’ may be invoked (Schacter and Tulving, 1994). As we will see, several disease states primarily affect one kind of memory, and many others affect more than one. Memory can be divided into those forms and systems that are declarative and those that are non-declarative. Declarative or explicit memory is memory for events that can be consciously recalled. Nondeclarative or

implicit memory, by comparison, is memory that is expressed as a change in behaviour, and is often unconscious. **See also:** Learning and memory; Neural information processing

## Episodic Memory

### Definition

Episodic memory is our personal, conscious, explicit recollection of experienced events as framed in our own context, and is therefore a type of declarative memory. It is the system we are usually referring to when we use the term ‘memory’. For example, in thinking back in your mind as to what you had for dinner last night, or what you did on

Advanced article

Article Contents

- Introduction
- Episodic Memory
- Semantic Memory
- Simple Classical Conditioning
- Procedural Memory
- Priming
- Working Memory
- Summary

doi: 10.1038/npg.els.0004052

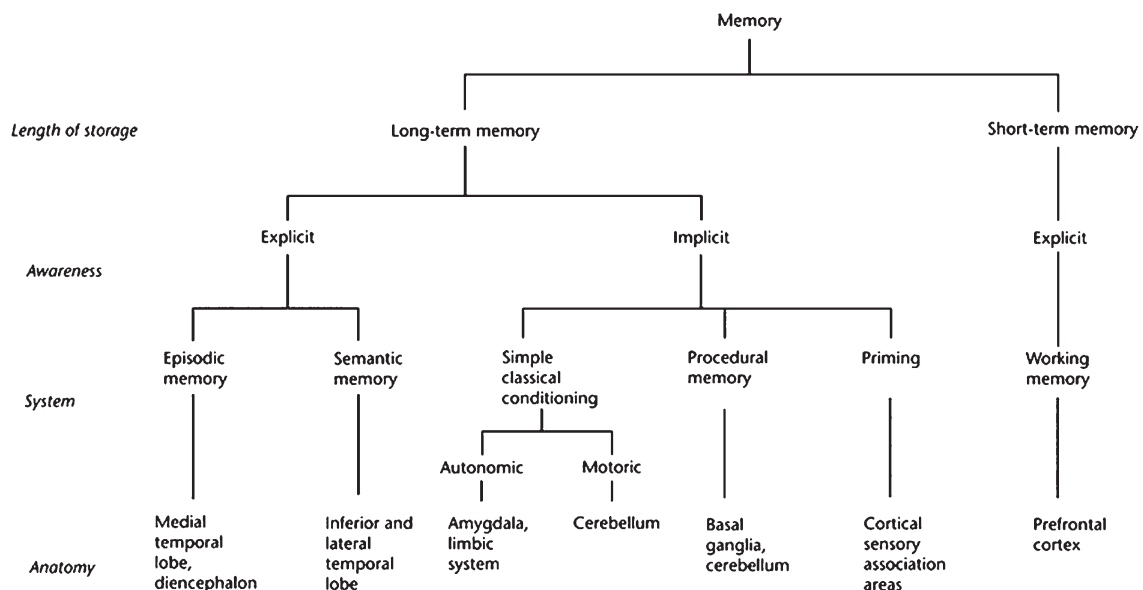


Figure 1 The six basic forms of memory.

**Table 1** Selective memory system disruptions in common clinical disorders

Disease	Episodic memory	Semantic memory	Simple classical conditioning	Procedural memory	Priming	Working memory
Alzheimer disease	+++	++	+	–	–perceptual +conceptual	++
Frontotemporal dementia	++	++	?	–	?	+++
Semantic dementia	+	+++	?	?	?	–
Lewy body dementia	++	?	?	?	?	++
Stroke and vascular dementia	+	+	±	+	±	++
Parkinson disease	+	+	–	+++	–	++
Huntington disease	+	+	–	+++	–	+++
Progressive supranuclear palsy	+	+	?	++	?	+++
Korsakoff syndrome	+++	–	+	–	±	±
Multiple sclerosis	+	±	±	?	–	++
Transient global amnesia	+++	±	?	–	–	–
Hypoxic–ischaemic injury	++	–	–	–	±	±
Head trauma	+	+	±	±	?	++
Tumours	±	±	±	±	±	±
Depression	+	±	?	++	?	±
Anxiety	+	–	±	–	±	±
Obsessive compulsive disorder	+	–	±	++	±	++
Attention deficit hyperactivity disorder	–	–	–	?	±	+

*Note:* + + +, Early and severe impairment; + +, moderate impairment; +, mild impairment; ±, occasional impairment or impairment in some studies but not others; –, no significant impairment; ?, unknown.

your last birthday, you are using your episodic memory system.

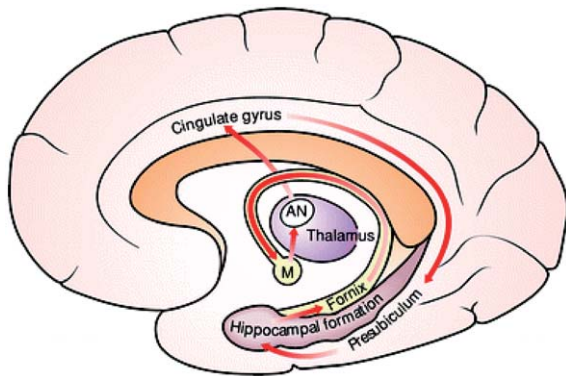
## Anatomy

In 1937 Papez proposed a neuroanatomical circuit for cortically processed information to be transferred in and out of the hippocampus through the cingulate gyrus (Figure 2). The importance of this circuit for memory was not appreciated, however, until patients with medial temporal lobe damage were found to have profound episodic memory impairment. These include the patients known as H.M., who underwent bilateral medial temporal lobe removal for treatment of intractable epilepsy, and R.B., who sustained damage to a single hippocampal region (CA1) from a hypoxic–ischaemic injury. Although we now know that there is increased complexity to the anatomy underlying episodic memory, most clinical disorders that disrupt episodic memory involve structures in the Papez circuit. **See also:** Hippocampus; Limbic system

## Clinical disorders of episodic memory

### Alzheimer disease

Alzheimer disease (AD) is the most common neurodegenerative disease in adulthood and the most common disease that affects the episodic memory system. The hippocampus and other medial temporal lobe structures are damaged by AD first, and to a greater extent than other brain areas. Patients with AD develop an amnesic disorder, leaving them impaired or unable to learn new information. Subsequently they begin to lose recently acquired knowledge. As discussed below, they suffer from distortions of memory that can impair their ability to live independently in addition to their failure to learn and retrieve information; for example, patients may believe that they turned off the stove when they have only thought about turning it off. Finally, as the pathology of AD begins to affect more widespread areas of the brain, these patients develop problems with other cognitive abilities and are unable to perform activities of daily living such as eating, dressing and bathing. **See also:** Alzheimer disease



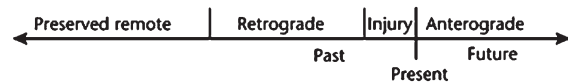
**Figure 2** The Papez circuit. Key components include the hippocampal formation, the fornix, the mammillary bodies (M), the anterior nucleus of the thalamus (AN), the cingulate gyrus and the presubiculum.

### Korsakoff syndrome

Korsakoff syndrome typically occurs when a chronic alcoholic patient suffers from poor nutrition and in particular develops thiamine deficiency. There is a loss of neurons and myelinated nerve fibres in several brain structures including the mammillary bodies, as well as the anterior, dorsomedial and laterodorsal thalamic nuclei. Because the damage to the mammillary bodies and anterior thalamic nucleus interrupts the Papez circuit, there is a profound loss of the ability to learn new information or to retrieve recently acquired memories. Insight, awareness, concern and motivation may also be blunted, whereas other cognitive functions are relatively preserved. Although Korsakoff syndrome is uncommon, the cognitive profile of these patients has been studied extensively because of the opportunity to examine patients with relatively selective cognitive and pathological deficits. Besides the inability to learn new information, patients with Korsakoff syndrome also suffer from memory distortions and outright confabulations. As is discussed below, these distorted memories are in part due to frontal lobe dysfunction secondary to damage of the dorsomedial thalamic nuclei that have robust connections to the frontal lobes. **See also:** Alcoholism; Thalamus; Thiamin diphosphate and vitamin B<sub>1</sub>

### Transient global amnesia

Transient global amnesia (TGA) is an uncommon disorder that is striking both for its selective neuropsychological dysfunction and for its temporary and benign nature. Although its aetiology is unknown, there appears to be an epidemiological relationship between TGA and migraine. Vascular events and seizures are also a consideration. Precipitants of TGA include psychological stress, bathing and physical exertion. Patients acutely develop a selective disorder of episodic memory, losing from several to 48 h of previously learned information and are unable to learn new information. Patients often repeatedly ask, 'Where am I?' and 'Why am I here?'. Other memory systems and



**Figure 3** Ribot's law. The injury can be due to any of the disorders described above, including the pathological changes of Alzheimer disease. The period of retrograde amnesia can last anywhere from several hours (in the case of transient global amnesia) to several years (in the case of surgical excision of the temporal lobes).

cognitive abilities are spared. Behaviour is otherwise normal, as are findings on neurological examination. There is no clouding of consciousness or loss of personal identity. Functional imaging studies, including positron emission tomography (PET), single-photon emission computed tomography (SPECT) and diffusion magnetic resonance imaging (MRI) have demonstrated abnormalities of Papez circuit. TGA resolves spontaneously, usually within 24 h. **See also:** Amnesia; Brain imaging: localization of brain functions; Migraine

### Other diseases

Other diseases can affect episodic memory by damaging the Papez circuit. These include infections (such as herpes simplex virus that has a predilection for the medial temporal lobes), tumours or other mass lesions (especially of the diencephalon), strokes (particularly of the thalamus), hypoxic–ischaemic injury such as follows cardiac arrest (the hippocampus is extremely vulnerable to this type of injury) and head trauma (frontal and temporal lobes are often injured). **See also:** Brain cancers; Herpes viruses (human); Hypoxia; Traumatic central nervous system injury

### Ribot's law

Memory loss in episodic memory and thus in the clinical disorders described above follows a particular pattern that has come to be known as Ribot's law: ability to learn new information is most impaired (anterograde amnesia), recently learned information cannot be retrieved (retrograde amnesia), and remotely learned information is spared (**Figure 3**).

### Distortions of episodic memory

In addition to outright failure of memory, disease states can cause distortions of memory. Schacter *et al.* (1996) have studied a patient with the initials B.G., who suffered a right frontal stroke. Although B.G. performed normally on standard tests of episodic memory, when given tests of memory that required him to distinguish individual items from groups of items with similar features, he showed a high rate of false-positive errors or 'false alarms'. In addition to these types of false alarms, patients with damage

or dysfunction of their frontal lobes exhibit deficits in their ability to determine the source of information, contextual information and the temporal order of events. **See also:** Stroke

### Vascular dementia

Patients with multi-infarct or vascular dementia, which often affects the cortex and underlying white matter of the frontal lobes, frequently suffer from these types of memory problems. For example, a patient we have treated was brought in by his family because of ‘memory problems’. The history revealed that he would frequently misattribute things said by one person to another, and he was confused as to when events occurred. His orientation was intact, and he performed normally (in fact, above average) on standard tests of episodic memory function, such as memory for a list of unrelated words. He performed extremely poorly, however, on tests that required him to distinguish individual items from groups of similar items, like the patient B.G. above. His MRI scan revealed numerous small strokes, most prominently affecting subcortical and cortical circuitry involving the frontal lobes.

Another patient we have treated for multi-infarct dementia suffered from an unusual type of memory distortion: she became convinced that events that occurred to a character on a television soap opera had actually happened to her own daughter!

### Frontal lobe dementia

Patients with frontal lobe (or frontotemporal) dementia also suffer from distortions of memory. In this illness, patients present with changes in personality as well as inability to inhibit inappropriate responses and difficulty in organizing and performing complex tasks. The memory of these patients is erratic both in daily life and on testing; often they perform poorly, but occasionally they are extremely accurate. They are typically oriented to person, place and time. These patients exhibit, however, all the memory difficulties and distortions that B.G. and patients with multi-infarct dementia show. In addition, they often show difficulties with encoding (learning) new information as well as with the effortful retrieval of previously learned information.

### Medial temporal and frontal lobes work together in episodic memory

Experiments in cognitive neuroscience are helping us to understand the contribution of the frontal lobes in episodic memory (Simons and Spiers, 2003). In a functional MRI study by Wagner *et al.* (1998), brain activation was measured while subjects were encoding lists of words. After a recognition test, activations were compared for words that were subsequently remembered versus those that were forgotten. In addition to the activation of left medial temporal

**Table 2** A filing analogy of episodic memory

Brain structure	Analogy
Frontal lobes	File clerk
Medial temporal lobes	Recent memory files
Other cortical regions	Remote memory files

regions, changes in activation of left prefrontal cortex also were seen and were correlated with successful encoding and retrieval. **See also:** Brain imaging: observing ongoing neural activity; Magnetic resonance imaging

The combination of these clinical and cognitive neuroscience findings leads us to a useful, if somewhat oversimplified, analogy: the frontal lobes are analogous to the ‘file clerk’ of the episodic memory system, the medial temporal lobes to the store of the ‘recent memory files’, and the other cortical regions to the repository of the ‘remote memory files’ (Table 2). Over time, as memories are consolidated, files are transferred from the medial temporal lobe stores to the other cortical regions. Thus, if the frontal lobes are not functioning properly, it is difficult (although possible) to get information in and out of storage. In addition, the information may be distorted due to improper filing leading to inaccurate source, context and temporal order. If the medial temporal lobes are not working, it is impossible to get recent information in and out of storage. Older information, already transferred out of medial temporal lobe structures and stored in other cortical regions, will still be available.

### Alzheimer disease revisited

Previously, when we discussed AD as the most common clinical cause of episodic memory dysfunction, we focused on the hippocampal dysfunction impairing the Papez circuit. However, patients with AD are also known to exhibit pathological, physiological and neuropsychological changes in the frontal lobes as the disease progresses. Thus, it might be expected that some patients with AD will exhibit similar types of memory distortions that patients with frontotemporal or multi-infarct dementia show. In fact, patients with AD do exhibit these types of memory distortions, and often these false memories cause much clinical concern. For example, patients who suffer only from a failure to retrieve information and cannot remember whether they have turned the stove off can check it again. Similarly, patients who have difficulty remembering whether they have taken their medication can use organizational strategies to aid their memory. Patients who falsely remember that they have turned the stove off or taken their medication when they have not, however, are no longer able to live independently. These and other memory distortions are common. In a study of their memory for where they were and what they were doing when

they heard the news of the September 11, 2001, terrorist attacks, patients with AD were three times more likely to falsely remember distorted information than to report that they did not remember the information (Budson *et al.*, 2004). We have begun to explore the memory distortions of these patients experimentally, and have found that, unlike healthy older adults, patients with AD are unable to inhibit false alarms to new words that are similar to studied words (Budson *et al.*, 2000). **See also:** Ageing and the brain

## Semantic Memory

### Definition

Semantic memory is our general store of conceptual and factual knowledge not related to any ‘specific’ memory. For example, when we recall who George Washington was, we are using our semantic memory system. Although we remember a number of facts and images about George Washington, most of us do not remember where and in what context we learned this information, but simply know these facts as isolated knowledge. Like episodic memory, semantic memory is a conscious, declarative and explicit memory system. We know this memory system is different from episodic memory because semantic memory is relatively spared in patients who have severe impairment of the episodic memory system and disruption of the Papez circuit, such as those with Korsakoff syndrome, TGA and surgical removal of the medial temporal lobes. **See also:** Learning and memory

### Anatomy

In its broadest sense, semantic memory includes all our knowledge of the world except for the recently learned episodic memory information, and thus could be argued to reside in virtually all cortical areas. There is increasing evidence, for example, that our visual image of George Washington is stored in or nearby visual association areas. However, a more narrow view of semantic memory, one that is more justified in light of the naming and categorization tasks by which it is usually measured, localizes semantic memory to the lateral temporal lobes, particularly in the left hemisphere.

Some of the most compelling research regarding the localization of semantic memory in this more narrow sense of linking names of objects to their concepts comes from the work of Damasio *et al.* (1996). First, they reported that patients with strokes in different regions of the lateral temporal lobes were more likely to exhibit difficulty retrieving the names of different categories of objects: patients with lesions of the left-temporal pole showed difficulty retrieving names of people; those with lesions of the left anterior–inferior temporal region showed difficulty retrieving names of animals; and those with lesions of the

left posterior–inferior temporal region showed difficulty retrieving names of tools. Second, they reported that similar, relatively specific, brain regions were activated with PET in normal individuals when retrieving names of people, animals or tools. Other studies of patients with brain lesions have suggested that whereas the left temporal lobe is more important for nouns, the left frontal lobe is more important for verbs. More recent work using functional imaging in healthy individuals suggests that a very similar brain network including left temporal and frontal lobes are active for both nouns and verbs. **See also:** Imaging: an overview; Language

### Clinical disorders of semantic memory

Not surprisingly, in addition to strokes, other clinical disorders that disrupt lateral temporal lobe structures tend to produce deficits of semantic memory.

#### Alzheimer disease

The most common clinical disorder that exhibits semantic memory deficits is AD. In addition to having pathology in medial temporal and prefrontal cortex, patients with AD show pathology in lateral temporal lobes. This is one reason why patients with AD have difficulty coming up with names not only of people (which is common in older adults) but also of other types of objects. Although we may be tempted to try to link the semantic memory deficit in AD to the episodic memory dysfunction, Green and Hodges (1996) have shown that these two memory systems decline independently in AD. It is the devastation of the semantic memory system that causes patients with AD ultimately to lose all knowledge about the world, even their own name and ability to recognize themselves in a mirror.

#### Semantic dementia

Patients with an extremely rare type of degenerative disorder, termed semantic dementia, exhibit deficits in all semantic memory functions, including naming, single-word comprehension and impoverished general knowledge, with relative preservation of other components of speech, perceptual and nonverbal problem-solving skills and episodic memory. These patients have a ‘two-way’ naming deficit: they are unable to name an item when it is described and they are also unable to describe the item when given its name. With their relatively spared anterograde and recent retrograde memory function in the setting of disrupted remote retrograde memory, patients with semantic dementia are said to exhibit a ‘reverse Ribot’ pattern (see **Figure 3**).

#### Other diseases

Other disease states that cause disruption of lateral temporal lobes and hence of semantic memory include encephalitis (which often affects the temporal lobes) and traumatic brain injury.

## Autobiographical memory

There remain several interesting and unresolved issues regarding autobiographical memory and its relationship to semantic memory. Case reports have been published of several patients who exhibited relatively selective loss of their remote autobiographical memory after suffering bilateral damage to the anterior portion of their lateral temporal lobes. These patients, like those with semantic dementia, exhibit a reverse Ribot pattern: they are able to remember recently learned information over minutes, days or weeks, but are unable to recall their remote past such as childhood and school memories, or memories of their parents, spouse, children, etc. These patients almost always have evidence of damage to other parts of the semantic memory system. The validity of the autobiographical memory literature has been questioned, because some patients present with an autobiographical amnesic syndrome that does not appear to be physiologically possible. For example, often following a minor head injury, a patient will not be able to remember his or her name or other autobiographical information, even though the episodic and semantic memory systems appear to be otherwise intact. Such an amnesia is often referred to as a ‘Hollywood amnesia’, and is thought to be of psychological origin. **See also:** Amnesia

## Simple Classical Conditioning

### Definition

Think of the famous case of Pavlov’s dog: simple classical conditioning involves the pairing of two stimuli – an unconditioned stimulus (the meat) and a conditioned stimulus (the bell). When paired together, the response (salivation) is elicited by the conditioned stimulus alone. This form of memory is an unconscious, nondeclarative or implicit one because conscious awareness, although often present, is not necessary for the learning to take place. The distinction between an autonomic conditioned response (such as a fear response) and a motoric conditioned response (such as an eyeblink) is often made. (Note that not all memory formed by pairing two items is simple classical conditioning; this type of pairing or associative memory can be formed using episodic memory as well. Associative episodic memory allows the retrieval of information by a ‘cue’ alone; for example, in contrast to questions such as, ‘What did you have for dinner two weeks ago?’ when given the cue ‘Have you seen *Star Wars*?’ the answer automatically pops into mind without active, effortful retrieval.) **See also:** Autonomic nervous system

### Anatomy

In a paper entitled ‘Double dissociation of conditioning and declarative knowledge relative to the amygdala and

hippocampus in humans’, Damasio and colleagues described three patients. The first, who had selective bilateral damage to the amygdala, had no difficulty remembering declarative facts but could not acquire a classical conditioning autonomic response. The second, who had selective bilateral hippocampal damage, failed to remember the declarative facts but did acquire the conditioning. The third, who had bilateral damage to both amygdala and hippocampus, acquired neither the conditioning nor the declarative facts (Bechara *et al.*, 1995). Thus, the amygdala and its connections are important for autonomic conditioning. In motoric conditioning, the cerebellum appears to play the most important role. **See also:** Cerebellum: anatomy and organization; Limbic system

## Clinical disorders of simple classical conditioning

Although neither patients nor their families will complain of difficulties with this form of memory, patients who have disruption of the amygdala, thalamus or cerebellum frequently show impairments of one or more types of simple classical conditioning. These include AD (due primarily to pathology in the amygdala), Korsakoff syndrome (from both cerebellar and mediodorsal thalamic nuclear damage) and degenerative diseases of the cerebellum. **See also:** Thalamus

## Procedural Memory

### Definition

Procedural memory is the ability to learn behavioural and cognitive skills and algorithms that operate on an automatic, unconscious level. Examples include riding a bike or driving a standard transmission automobile. Because procedural memory is spared in patients with severe deficits of the episodic memory system, such as those with Korsakoff syndrome, AD and surgical removal of the medial temporal lobes, we know that procedural memory represents a separate and distinct memory system.

### Anatomy

Cognitive neuroscience research using functional neuroimaging has shown that brain regions involved in procedural memory, such as the basal ganglia and the cerebellum, become active once a new task has been learned. Sleep is important in such learning; improvement in accuracy and performance speed after practice of a specific motor sequence occur across a night of sleep but not during waking periods of 4–12 h (Walker *et al.*, 2003). As is described below, diseases that affect the basal ganglia (e.g. Parkinson disease and Huntington disease) or cerebellum (e.g. olivopontocerebellar degeneration) or both (e.g. strokes) can

impair the procedural memory system. **See also:** Basal ganglia and the regulation of movement; Cerebellum: movement regulation and cognitive functions

## Clinical disorders of procedural memory

Numerous studies of patients with dysfunction of cerebellar or basal ganglia structures have demonstrated deficits in procedural memory.

### Strokes

One example is of a young man we have cared for, who suffered from a stroke in the left putamen. He lost the ability to perform most automatic, skilled movements, such as the act of writing and swinging a golf club. Although he has been able to relearn the fundamentals of these skills, even several years later they continue to require explicit thinking: he lost much of the automatic effortless-ness of simple motor tasks that most of us take for granted. Difficulties in learning procedural skills are similarly seen in patients with strokes of the cerebellum.

### Degenerative and other diseases

In addition to strokes, almost any cause of basal ganglial or cerebellar damage, such as haemorrhages and tumours, can impair skill learning. Degenerative diseases that affect the basal ganglia and cerebellum, however, are the most common causes of procedural memory disorders (see Salmon *et al.*, 1998, for a review). In Parkinson disease (PD), degeneration occurs in the substantia nigra of the midbrain, leaving the striatum in the basal ganglia depleted of dopamine and therefore dysfunctional. In Huntington disease (HD), degeneration occurs primarily in the caudate nucleus of the striatum and is probably related to abnormal expression of the protein huntingtin. Many studies have compared patients with AD to those with HD or PD. Because the pathology of AD affects cortical and limbic structures while sparing basal ganglia and cerebellar structures, patients with AD show deficits of episodic memory but acquire procedural skills at a normal rate. Early in the disease, patients with HD and PD demonstrate near-normal episodic memory performance, but show impairments in their ability to acquire skill learning. Similarly, patients with cerebellar degeneration (e.g. olivopontocerebellar degeneration) also show deficits in procedural memory. **See also:** Huntington disease; Parkinson disease

## Rehabilitation potential

As we have discussed, because procedural memory depends upon structures independent of those necessary for episodic memory, patients with damage to medial temporal lobe structures or other parts of the Papez circuit can still learn procedural tasks. This fact provides an opportunity for rehabilitation of young patients who have damage to the

episodic memory system. Glisky and Schacter (1989) reported their work with a 32-year-old woman who suffered near complete loss of episodic memory following a bout of encephalitis. They were able to use her preserved procedural memory, and some priming as well, to teach her over 250 discrete pieces of new information that allowed her to perform her job accurately and efficiently in the workplace.

## Priming

### Definition

Broadly defined, priming occurs when a prior encounter with a particular item changes how one responds to the current item. Priming is often studied using the word stem completion task: after initially studying words (e.g. octopus), subjects are more likely to complete a three-letter stem (e.g. oct- - -) with a studied word versus an unstudied one (e.g. octagon). Because this phenomenon occurs even if the subject does not consciously remember encountering the prior item, priming is an implicit form of memory. Priming often is divided into perceptual priming, which is modality specific (e.g. auditory, visual) and not dependent upon the depth of encoding at study, and conceptual priming, which is not modality specific and does benefit from elaborate encoding (example: study item 'sea creatures', test 'oct- - -'). We will focus on the more studied perceptual priming.

### Perceptual priming: anatomy

Tulving and Schacter have proposed that perceptual priming depends upon a perceptual representation system (see Schacter and Buckner, 1998, for a review). This system is involved in processing information about the form and structure of items, but not their meaning. Support for this type of system includes the finding that perceptual priming of words is greater when the study and test items are in the same font and case (upper versus lower). Two converging pieces of evidence suggest that posterior cortical regions involved in the processing of sensory information are important for perceptual priming. First, Gabrieli and colleagues studied a patient, M.S., who had his right occipital lobe removed for intractable epilepsy. M.S. demonstrated normal conceptual priming and episodic memory while failing to show perceptual priming. Second, neuroimaging studies of visual perceptual priming using PET and functional MRI show changes in activation of visual peristriate cortex.

## Clinical disorders of perceptual priming

In theory, any large lesion of sensory association cortex, particularly on the right, could cause a deficit of perceptual priming. In practice, patients like M.S. do not miss their priming abilities, and thus such patients are identified only

in an experimental setting. Patients with degenerative diseases, such as AD, PD and HD, demonstrate normal perceptual priming. **See also:** Sensory systems in vertebrates: general overview

## Working Memory

### Definition

Working memory (WM) refers to the ability to maintain and manipulate information 'on-line' to assist in goal-oriented behaviour. Because it requires active conscious participation, WM is an explicit or declarative memory system. WM has traditionally been divided into components that process phonological versus visuospatial information, as well as a 'central executive' system that allocates attentional resources. A common example of using phonological WM is silently repeating a seven-digit phone number until you have a chance to write it down. When you give someone directions by mentally following a route, you are using your spatial WM.

### Anatomy

Numerous studies of animals and humans have found that WM uses a network of cortical and subcortical areas, which differ depending upon the particular task. However, virtually all working memory tasks require participation of the prefrontal cortex. Typically, the network includes posterior brain regions (such as visual association areas) that are linked with prefrontal regions to form a circuit. As expected, studies have shown that phonological WM tends to involve more left-sided brain regions, while spatial WM tends to involve more right-sided ones. However, studies have also shown that more difficult WM tasks require bilateral brain activation, regardless of the nature of the material being manipulated. Furthermore, there is also an increase in the number of activated brain regions in the prefrontal cortex as the complexity of the task increases.

### Clinical disorders of working memory

Because WM is dependent upon a network of activity that includes subcortical structures as well as anterior and posterior cortical regions, many neurodegenerative diseases show impairment in WM tasks. Studies have demonstrated that patients with PD, HD, AD and less common disorders such as progressive supranuclear palsy are impaired on tasks of spatial WM (see Owen *et al.*, 1998, for a review). In addition to neurodegenerative diseases, almost any disease process that disrupts the frontal lobes or their connections to posterior cortical regions and subcortical structures can interfere with WM. Such processes include strokes, tumours, head injury and multiple sclerosis, among others. Although the pathophysiology is yet to be worked out,

disorders that diminish attentional resources, such as attention deficit disorder, obsessive compulsive disorder and depression can also impair WM. Lastly, if attentional resources cannot be adequately focused on information that needs to be encoded for later retrieval, then WM deficits can also impair episodic memory performance. **See also:** Attention deficit-hyperactivity disorder; Mood disorders

## Summary

Although memory may appear as a unitary concept, in this article we have reviewed evidence that it is in fact composed of separate and dissociable forms of memory. We have focused primarily on the episodic memory system, discussed how this system can be affected by diseases affecting the medial temporal lobes, the limbic system or the frontal lobes, and how memory distortions may result. We then briefly discussed the other forms of memory, which diseases affect them and how these contrast with the episodic memory system. Lastly, we mentioned some of the cognitive neuroscience research that has allowed us to understand these different forms of memory. We are confident that continued research into memory and memory diseases will ultimately provide assistance to all patients who suffer from memory disorders.

## References

- Bechara A, Tranel D, Damasio H *et al.* (1995) Double dissociation of conditioning and declarative knowledge relative to the amygdala and hippocampus in humans. *Science* **269**: 115–118.
- Budson AE, Daffner KR, Desikan R and Schacter DL (2000) When false recognition is unopposed by true recognition: Gist based memory distortion in Alzheimer's disease. *Neuropsychology* **14**: 277–287.
- Budson AE, Simons JS, Sullivan AL *et al.* (2004) Memory and emotions for the September 11, 2001, terrorist attacks in patients with Alzheimer's disease, patients with mild cognitive impairment, and healthy older adults. *Neuropsychology* **18**: 315–327.
- Damasio H, Grabowski TJ, Tranel D, Hichwa RD and Damasio AR (1996) A neural basis for lexical retrieval. *Nature* **380**: 499–505.
- Gliksy EL and Schacter DL (1989) Extending the limits of complex learning in organic amnesia: computer training in a vocation domain. *Neuropsychologia* **27**: 173–178.
- Green JD and Hodges JR (1996) Identification of famous faces and famous names in early Alzheimer's disease. Relationship to anterograde episodic and general semantic memory. *Brain* **119**: 111–128.
- Owen AM, Sahakian BJ and Robbins TW (1998) The role of executive deficits in memory disorders in neurodegenerative disease. In: Troster AI (ed.) *Memory in Neurodegenerative Disease: Biological, Cognitive, and Clinical Perspectives*, pp. 157–171. Cambridge, UK: Cambridge University Press.
- Salmon DP, Lineweaver TT and Heindel WC (1998) Nondeclarative memory in neurodegenerative disease. In: Troster AI (ed.) *Memory in Neurodegenerative Disease: Biological, Cognitive, and Clinical Perspectives*, pp. 210–225. Cambridge, UK: Cambridge University Press.
- Schacter DL and Buckner RL (1998) Priming and the brain. *Neuron* **20**: 185–195.
- Schacter DL and Tulving E (1994) What are the memory systems of 1994? In: Schacter DL and Tulving E (eds) *Memory Systems 1994*, pp. 1–38. Cambridge, MA: MIT Press.

- Schacter DL, Curran T, Galluccio L, Milberg W and Bates J (1996) False recognition and the right frontal lobe: a case study. *Neuropsychologia* **34**: 793–808.
- Simons JS and Spiers HJ (2003) Prefrontal and medial temporal lobe interactions in long-term memory. *Nature Reviews Neuroscience* **4**: 637–648.
- Wagner AD, Schacter DL, Rotte M *et al.* (1998) Building memories: remembering and forgetting of verbal experiences as predicted by brain activity. *Science* **281**: 1188–1191.
- Walker MP, Brakefield T, Hobson JA and Stickgold R (2003) Dissociable stages of human memory consolidation and reconsolidation. *Nature* **425**: 616–620.
- Gazzaniga M (2000) *The New Cognitive Neurosciences*. Cambridge, MA: MIT Press.
- Perry RJ and Hodges JR (1996) Spectrum of memory dysfunction in degenerative disease. *Current Opinion in Neurology* **9**: 281–285.
- Schacter DL (1996) *Searching for Memory: The Brain, the Mind, and the Past*. New York: Basic Books.
- Schacter DL (2001) *The Seven Sins of Memory: How the Mind Forgets and Remembers*. Boston: Houghton-Mifflin.
- Schacter DL and Tulving E (1994) *Memory Systems 1994*. Cambridge, MA: MIT Press.
- Squire LR and Kandel ER (1999) *Memory: From Mind to Molecules*. New York: Scientific American Library.
- Squire LR and Schacter DL (2002) *Neuropsychology of Memory*. New York: Guilford Press.
- Troster AI (1998) *Memory in Neurodegenerative Disease: Biological, Cognitive, and Clinical Perspectives*. Cambridge, UK: Cambridge University Press.
- Feinberg TE and Farah MJ (1997) *Behavioural Neurology and Neuropsychology*. New York: McGraw-Hill.

## Further Reading