

Disruption of the Ventral Visual Stream in a Case of Reduplicative Paramnesia

ANDREW E. BUDSON,^{a,b,c,d} HEIDI L. ROTH,^e DORENE M. RENTZ,^{b,c,f}
AND MICHAEL RONTAL^{c,f}

^b*Division of Cognitive and Behavioral Neurology, Brigham and Women's Hospital, Boston, Massachusetts, USA*

^c*Harvard Medical School, Boston, Massachusetts, USA*

^d*Department of Psychology, Harvard University, Cambridge, Massachusetts, USA*

^e*Department of Neurology, University of Florida, Gainesville, Florida, USA*

^f*Department of Neurology, Beth Israel Deaconess Medical Center, Boston, Massachusetts, USA*

INTRODUCTION

Reduplicative paramnesia (RP), a syndrome named by Pick in 1903 to describe a specific and limited disturbance of memory, is characterized by a subjective certainty that a familiar place or person has been duplicated.¹ Most often seen in post-traumatic brain injuries, this syndrome has been described in a variety of neurologic conditions, including strokes, intracerebral hemorrhages, tumors, dementias, encephalopathies, and various psychiatric conditions.² The classic and most commonly described neuroanatomical localization is the combination of bilateral frontal lobe and right hemisphere lesions.^{3,4} Although many theories have been advanced to explain how these lesions could produce this syndrome, the specific pathophysiology is unknown. We report a patient who provides anatomical and neuropsychological support for the theory that RP is a syndrome that may develop in a vulnerable brain by a lesion in the ventral visual stream, disrupting communication between the visual cortex and both visual processing areas in the inferior temporal lobe and visual memory in the nondominant parahippocampal region.

CASE REPORT

The patient, OB, was a 45-year-old left-handed man with a history of alcoholism, diabetes, and hypertension, who had been admitted to the hospital for a minor operation. Two weeks prior to admission, he stopped drinking. Ten days into his hospital stay, the nursing staff reported that OB was "confused," not knowing where his room was. The neurology service was consulted. Most of the bedside mental status examination, carried out in his hospital room, was normal, including being oriented to

^aAddress for correspondence: Andrew E. Budson, Division of Cognitive and Behavioral Neurology, Brigham and Women's Hospital, 221 Longwood Avenue, Boston, MA 02115. Tel.: (617) 732-8060; fax: (617) 738-9122.
e-mail: abudson@yahoo.com

“Boston, Beth Israel Hospital, 7th floor.” However, when OB was asked to put on his glasses for the visual exam, he pointed to his roommate’s bed and said that the glasses were in his “other room,” explaining that we were presently in his “room in the hallway.” When pressed about why he should have a room in the hallway and why he should have two rooms, he acknowledged that he was unable to resolve these contradictions. Over the next few days, when questioned as to where he was (when in his hospital room), he again sometimes reported that he was in his room in the hallway and at other times that he was in his room at his house. At all times, he believed that he had “another room” that was located in the correct place in the hospital, although he never reported being in this “other room.”

He was not concerned about his orientation difficulties. He was able to provide a coherent history of his hospitalization. His neurological examination was significant for mild clumsiness and autotopagnosia (incorrect somatotopic localization) of the right hand. Neuropsychological testing was obtained, revealing decreased performance of complex attention and response inhibition tasks, mild right-sided neglect, and moderately impaired visuospatial integration and visual memory (see TABLE 1 for these and other results). An electroencephalogram and lumbar puncture were obtained. Brain MRI revealed a small, linear, nonenhancing lesion in the white matter of the left temporo-parieto-occipital junction, which was hyperintense on T2 and proton density images and isointense on T1, consistent with a subacute stroke (see FIG. 1). The duplication of his hospital room persisted throughout the remainder of his hospitalization. In follow-up visits to the neurology clinic, although his paramnesia and autotopagnosia had resolved, he now complained of memory problems.

DISCUSSION

Explanations as to the etiology of RP began with Pick, who hypothesized that his patient produced the duplication due to a “convulsive attack” interrupting conscious memory.¹ Weinstein and Kahn postulated a psychodynamic theory based upon a patient’s denial of illness.⁵ Benson, Gardner, and Meadows studied three patients with traumatic brain injury, all of whom had both right hemisphere and bifrontal damage.³ They suggested that the right hemisphere injury rendered patients unable to correctly update their orientation due to impaired visuospatial perception and visual memory, while their frontal lobe dysfunction left them unable to resolve the conflict that inevitably arose when the assumptions of their orientation were challenged. Other authors have also found disruption of visual perception, including facial recognition, in patients with Capgras syndrome (CS), a subset of RP in which close acquaintances are regarded as imposters.^{4,6–8} Because CS can be thought of as the “mirror image” of prosopagnosia, Ellis and Young hypothesized that it was likely due to a lesion that disrupts the dorsal visual stream.⁶ In their discussion of a case of a patient with CS in the visual (but not the auditory) modality, Hirstein and Ramachandran argued that it was more likely that this syndrome would be caused by disruption of the ventral visual stream, producing in their patient a failure of communication between the temporal lobe and the limbic complex.⁹ Imaging studies of this patient, however, did not show the specific lesion that they postulated.

Our patient developed a reduplicative paramnesic disturbance specific to the location of his room following a small left hemisphere stroke. Although one might ar-

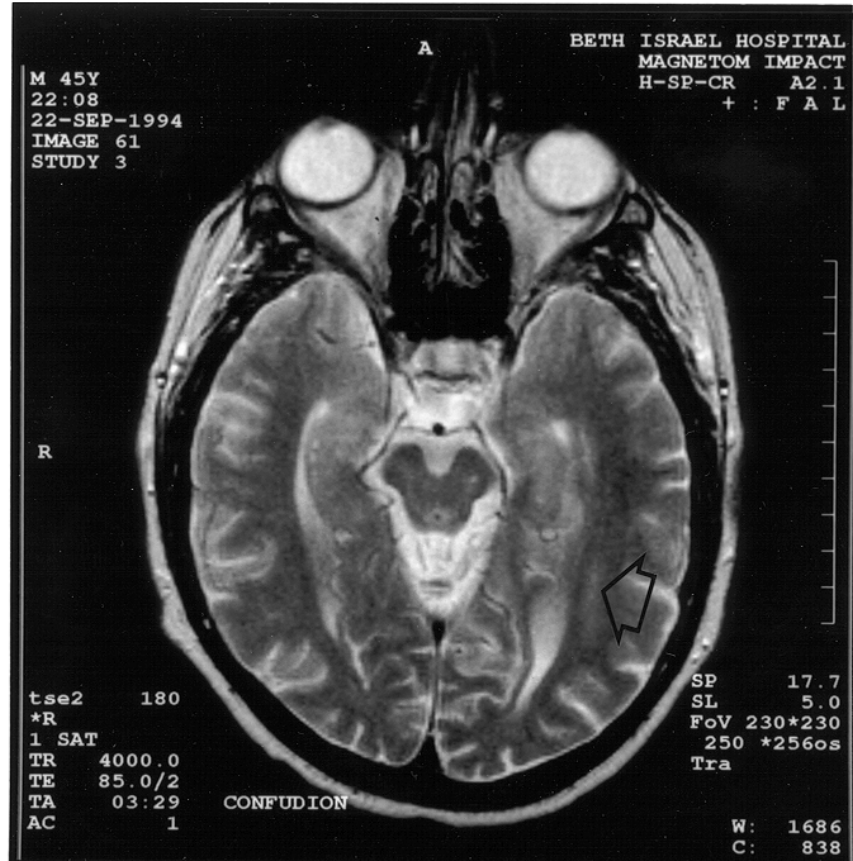


FIGURE 1. T2-weighted axial MRI image demonstrating a small, linear area of hyperintensity consistent with a subacute stroke (arrow) in the white matter adjacent to Brodmann areas 19 and 37, a localization consistent with the occipitotemporal projection system, the fiber pathway of the ventral visual stream.¹⁰ Location of the stroke was confirmed by lesion analysis as described by Damasio and Damasio.¹³

gue that his paramnesia may have been part of a more general confusional state, this is unlikely given that he showed no evidence of confusion other than for the location of his room, he had no difficulty in providing a coherent history of recent events, and he performed well on tests of simple attention such as Digit Span (7 forward, 7 backward). The stroke damaged the white matter adjacent to Brodmann areas 19 and 37 and most likely disrupted the occipitotemporal projection system, the fiber pathway of the ventral visual stream.¹⁰ This disruption, interfering with the communication between the visual cortex and both visual processing areas in the inferior temporal lobe and visual memory of the nondominant parahippocampal region, can explain OB's difficulty with tests of visuospatial perception and visual memory. Our left-handed patient may also have reversed dominance for visual memory, which would

TABLE 1. Results and interpretation of tests and examinations

Tests and examinations	Results	Interpretation
Bedside mental status testing		
Months backward	Intact	Normal
Calculations	Intact	Normal
Confrontational naming	Intact	Normal
Comprehension of complex commands	Intact	Normal
Writing a sentence	Intact	Normal
Repetition	Intact	Normal
Right/left confusion	Absent	Normal
Finger agnosia	Absent	Normal
Recent memory: current events	Intact	Normal
Remote memory: personal history	Intact	Normal
Copy 3-dimensional figure	Normal	Normal
Clock drawing	Intact	Normal
Neurological examination		
Cranial nerves including vision	Intact	Normal
Strength	Normal	Normal
Reflexes	Loss of ankle reflexes	Abnormal
Sensation—General	Mild peripheral neuropathy	Abnormal
Two-point discrimination	Intact	Normal
Autotopagnosia (somatotopic localization)	Mild disruption on right hand	Abnormal
Stereognosis & graphesthesia	Intact	Normal
Coordination	Mild right-sided clumsiness	Abnormal
Plantar reflexes	Flexor	Normal
Asterixis	Absent	Normal
Neuropsychological tests¹²		
General Intelligence		
American National Adult Reading Test	Est. IQ = 118	High average
Simple and complex attention		
Digit Span	7F, 7B	High average
Trails A	58 s, 10th percentile	Mild to moderate impairment
Trails B	115 s, 15th percentile	Mild to moderate impairment
Response inhibition		
Short Stroop	67 s, 2 errors	Mild to moderate impairment
Verbal fluency		
Word generation: F words	20 words	High average
Word generation: animals	18 words	High average
Language		
Boston Naming Test	55/60	Average
Verbal memory		
Wechsler: Logical Memory I—immediate	32nd percentile	Average
Wechsler: Logical Memory II—delayed	62nd percentile	Average
Visual memory		
Wechsler: Visual Memory I—immediate	32nd percentile	Average

— continued

TABLE 1. Results and interpretation of tests and examinations

Tests and examinations	Results	Interpretation
Wechsler: Visual Memory II—delayed	12th percentile	Mild to moderate impairment
Visuospatial ability		
Hooper Visual Organization Test	15/25	Moderate impairment
Ravens Colored Matrices	5th percentile, est. visual IQ = 75	Moderate to severe impairment
Visuospatial attention		
Letter cancellation test	Mild right-sided omissions	Mild impairment
Lumbar puncture	Unremarkable	Normal
Electroencephalogram	Transient bi-temporal and independent left mid-temporal theta activity with hyperventilation	Abnormal
Brain MRI (see FIG. 1)	Left posterior stroke	Abnormal

explain why the disturbance of left parahippocampal pathways could more likely produce the syndrome in his case. (Support for the possibility of reversed dominance comes from the fact that, with a left-sided lesion, our patient's verbal memory was above average and his visual memory—a “nondominant” hemisphere function—was impaired.) In addition, OB had evidence of frontal lobe dysfunction, as can be seen in his poor performance on tests of complex attention and response inhibition. Alcoholism has been shown to be a cause of selective bifrontal dysfunction¹¹ and is most likely the cause of his difficulty with those tests. Our patient thus provides radiologic evidence to support the theory that the critical pathology in RP is the combination of disruption of the ventral visual stream of the nondominant hemisphere, leading to inaccurate orientation, and bifrontal dysfunction that allows this inaccurate and confused orientation to be tolerated.

ACKNOWLEDGMENTS

We thank Daniel Z. Press, Jeremy D. Schmahmann, and Kirk R. Daffner for their thoughtful discussions.

REFERENCES

- PICK, A. 1903. Clinical studies: III. On reduplicative paramnesia. *Brain* **26**: 260–267.
- FORSTL, H., O.P. ALMEIDA, A.M. OWEN, A. BURNS & R. HOWARD. 1991. Psychiatric, neurological, and medical aspects of misidentification syndromes: a review of 260 cases. *Psychiatr. Med.* **21**: 905–910.
- BENSON, D.F., H. GARDNER & J.C. MEADOWS. 1976. Reduplicative paramnesia. *Neurology* **26**: 147–151.
- ALEXANDER, M.P., D.T. STUSS & D.F. BENSON. 1979. Capgras syndrome: a reduplicative phenomenon. *Neurology* **29**: 334–339.

5. WEINSTEIN, E.A. & R.L. KAHN. 1955. Denial of Illness: Symbolic and Physiological Aspects. Thomas. Springfield, IL.
6. ELLIS, H.D. & A.W. YOUNG. 1990. Accounting for delusional misidentifications. *Br. J. Psychiatry* **157**: 239–248.
7. ELLIS, H.D. 1994. The role of the right hemisphere in the Capgras delusion. *Psychopathology* **27**: 177–185.
8. SILVA, J.A. & G.B. LEONG. 1995. Visual-perceptual abnormalities in delusional misidentification. *Can. J. Psychiatry* **40**: 6–8.
9. HIRSTEIN, W. & V.S. RAMACHANDRAN. 1997. Capgras syndrome: a novel probe for understanding the neural representation of the identity and familiarity of persons. *Proc. R. Soc. Lond.* **264**: 437–444.
10. TUSA, R.T. & L.G. UNGERLEIDER. 1985. The inferior longitudinal fasciculus: a reexamination in humans and monkeys. *Ann. Neurol.* **18**: 583–591.
11. HAKIM, H., N.P. VERMA & M.F. GREIFFENSTEIN. 1988. Pathogenesis of reduplicative paramnesia. *J. Neurol. Neurosurg. Psychiatry* **51**: 839–841.
12. LEZAK, M.D. 1995. *Neuropsychological Assessment*. Oxford Univ. Press. London/New York.
13. DAMASIO, H. & A.R. DAMASIO. 1989. *Lesion Localization in Neuropsychology*. Oxford Univ. Press. London/New York.